

PATIENT HISTORY

The male patient was 54 at the time of the procedure, a heavy smoker with diabetes. During the visual examination, inadequate oral home care was noted. There were 12mm probing depths on the distal of #9 and the mesial of #10. The pre-op PA revealed corresponding radiographic bone loss. Tooth #10 was exfoliating with grade 3 mobility and #9 was diagnosed as grade 2 mobility.


TREATMENT APPROACH

The patient chose the LANAP protocol, in the attempt to save his teeth despite a hopeless prognosis on tooth #10. Per the LANAP protocol, the whole mouth was treated with the PerioLase MVP-7. Laser energy was used to decontaminate the pocket and upregulate (something). Piezo scaler tips were used to remove calculus and stimulate angiogenesis. The PerioLase MVP-7 was used a second time to achieve hemostasis, activate growth factors, and create a stable, sealed environment. Initial occlusal adjustment was performed per the LANAP protocol.

RESULTS

The patient did not return to our office for 8 years. Occlusal adjustment was not done routinely per the LANAP protocol due to lack of patient presentation, and oral home care was still visually inadequate. However, probing depths that were 12mm+ interproximally pre-LANAP treatment are now 4-5mm without mobility. The post-op PA radiograph shows bone regeneration and increase in bone density.

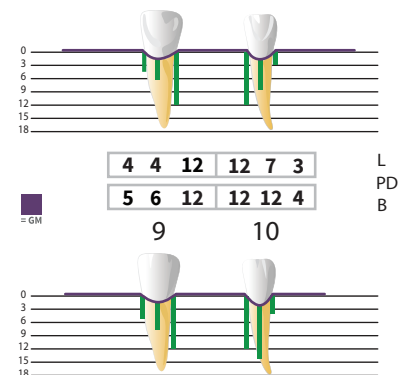
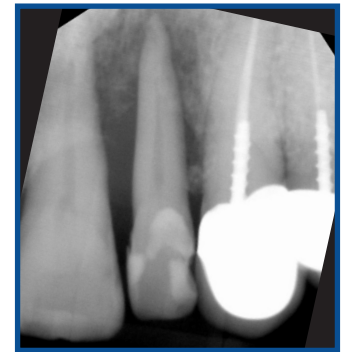Despite the hopelessness of the case, the extent of bone achieved was significant - virtually a complete reversal - and the patient now has the potential to retain his teeth for a lifetime.



**ABOUT THE AUTHOR:
DAVID MANGOT, DMD**

Dr. Mangot received his Doctor of Dental Medicine degree in 1987 from the University of Medicine and Dentistry of New Jersey (now Rutgers School of Dental Medicine). Following a General Practice Residency at Englewood Hospital from 1987-1988, Dr. Mangot continued with his post-graduate studies at the University of Medicine and Dentistry of New Jersey and went on to receive his Certificate in Periodontics in 1990. Dr. Mangot is an attending periodontist in the Department of Dentistry at the Hackensack University Medical Center. Dr. Mangot received his training and certification in the LANAP and LAIP protocol in 2010. Dr. Mangot is a Diplomate of the American Board of Periodontology and is a member of the American Academy of Periodontology and the American Dental Association.

Pre-Op



8 Years Post-Op

